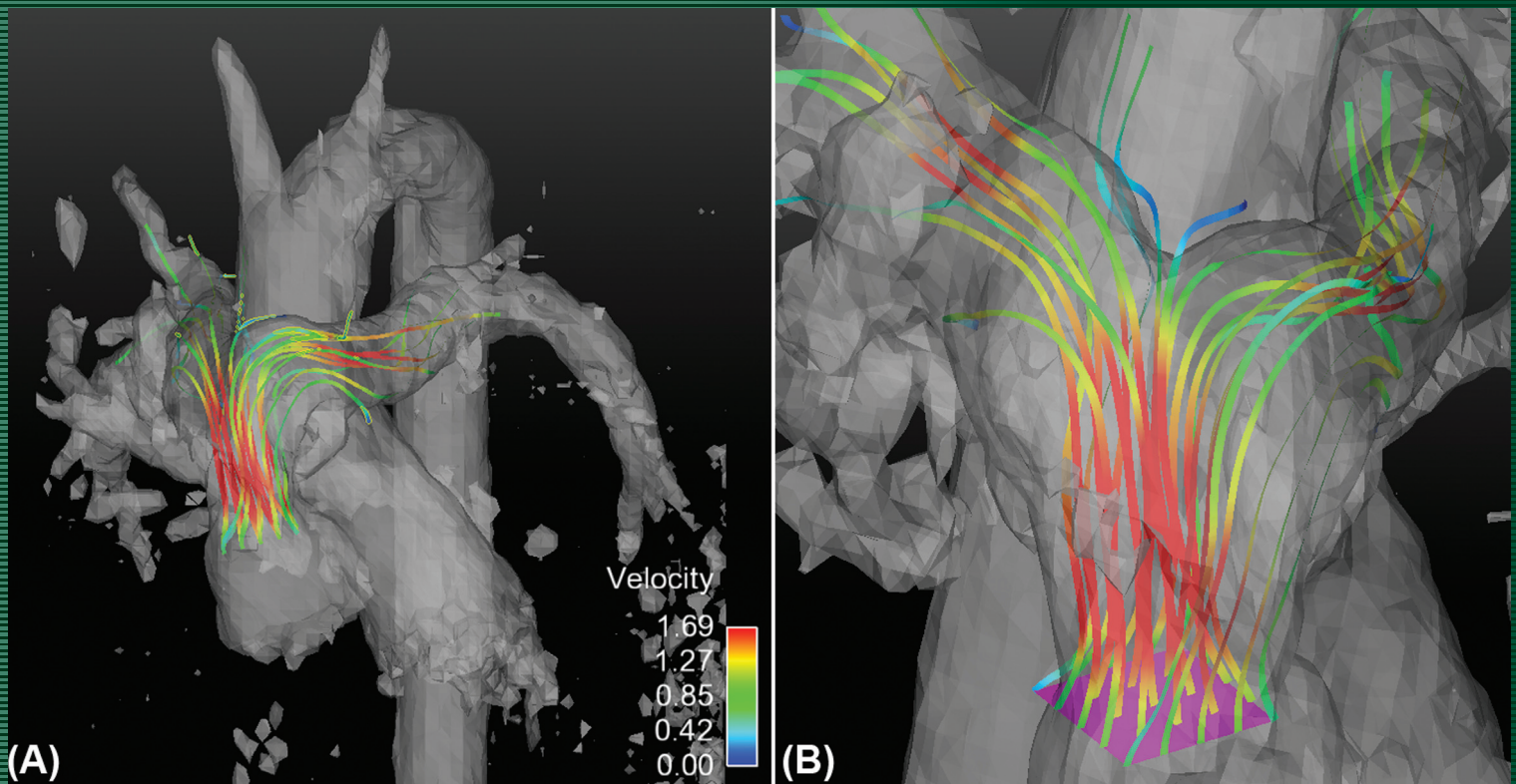


JMIRI

Journal of Magnetic Resonance Imaging

AN OFFICIAL JOURNAL OF THE INTERNATIONAL SOCIETY FOR MAGNETIC RESONANCE IN MEDICINE



THE RECONSTRUCTED VELOCITY FIELD IN ONE OF THE PATIENTS WITH REPAIRED TGA (LECOMPTE PROCEDURE). A: THE STREAMLINES PASSING THROUGH THE PULMONARY VALVE. B: THE LOCATIONS WHERE THE STREAMLINES ORIGINATED. FROM THE ARTICLE BY FALAHATPISHEH ET AL. (PP 1313-1319)